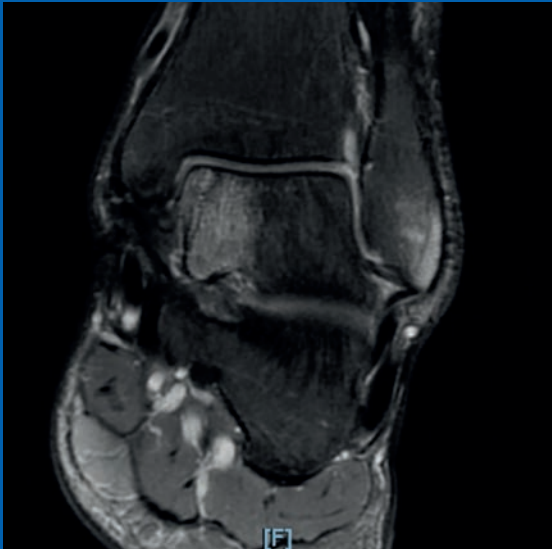

AMIC® Chondro-Gide® in the Ankle Joint



More than
10 Years of Clinical
Experience



Chondral and osteochondral Lesions (OCL) of the ankle are common and increasingly recognized as a source of persistent ankle pain.

Most osteochondral lesions of the talus (OLTs) are due to trauma and repetitive microtrauma.¹ Approximately 50% of ankle sprains and up to 73% of ankle fractures result in cartilage injury and can cause symptoms.²

The numerous factors that influence the occurrence, type, and evolution of an OCL are now well understood. However, the underlying pathophysiology is not.

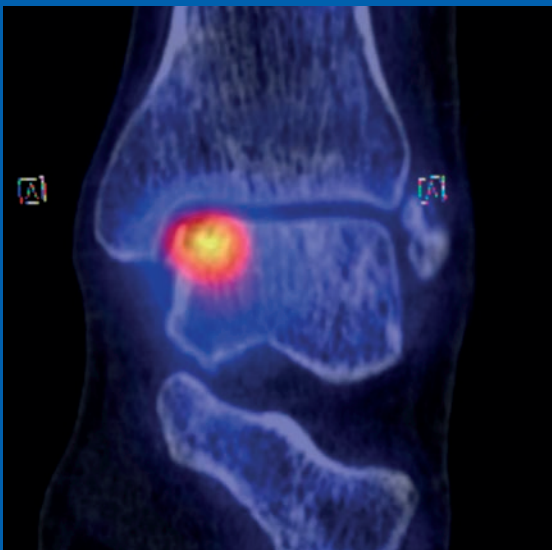
Researchers have developed multiple classification systems based on imaging systems. In 1959, Berndt and Harty introduced radiographic staging.³ In 1990, Ferkel⁴ developed a CT-based classification system. In 1999, Hepple et al.⁵ developed a system based on MRI. Arthroscopy is also useful in staging talar OCL, but cannot be used to fully assess underlying bony lesions.

With developments in diagnostic arthroscopy, magnetic resonance imaging (MRI), and computed tomography (CT), earlier and more precise detection is now possible.

MRI can provide a comprehensive assessment of articular cartilage and whether subchondral inflammatory changes are present. It can also help identify the depth of the chondral lesion.⁶

CT scans provide better visualization of the subchondral bone. However, some lesions may require both MRI and CT for adequate detection, evaluation, and treatment.

Still, the surgeon's recommended treatment cannot be based on imaging techniques alone. Clinical symptoms like pain and instability should also be considered.⁷



Active ankle osteochondral Lesion of the medial Talus.
Magnetic resonance tomography (MRT) and corresponding SPECT-CT: Single photon emission computed tomography (SPECT) plus computed tomography (CT)
Images courtesy of Prof. Dr. Victor Valderrabano

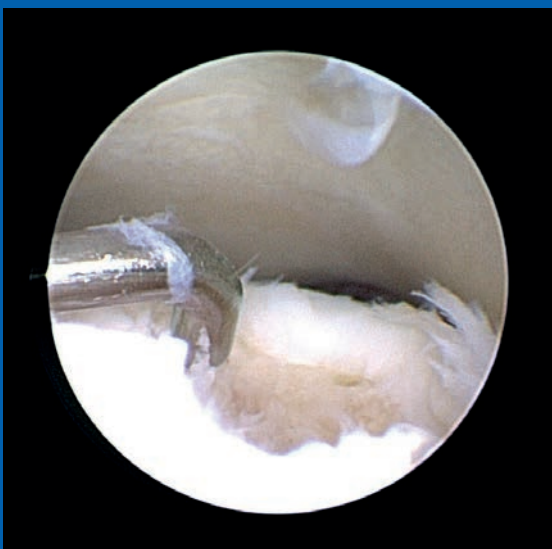

Image courtesy of Dr. Achim Preiss

AMIC[®] for Cartilage Regeneration

Your Challenge

As an orthopedic surgeon today, you face a growing number of treatment challenges. Your patients are living longer, more active lives than previous generations. At the same time, obesity rates are rising.

Active patients with cartilage damage expect a quick return to sports. Baby boomers want to stay active as long as possible, and avoid invasive surgical treatments.

With these changes in demographics, mindsets, and lifestyles, finding more regenerative treatment approaches for your patients will be critical in the coming years.

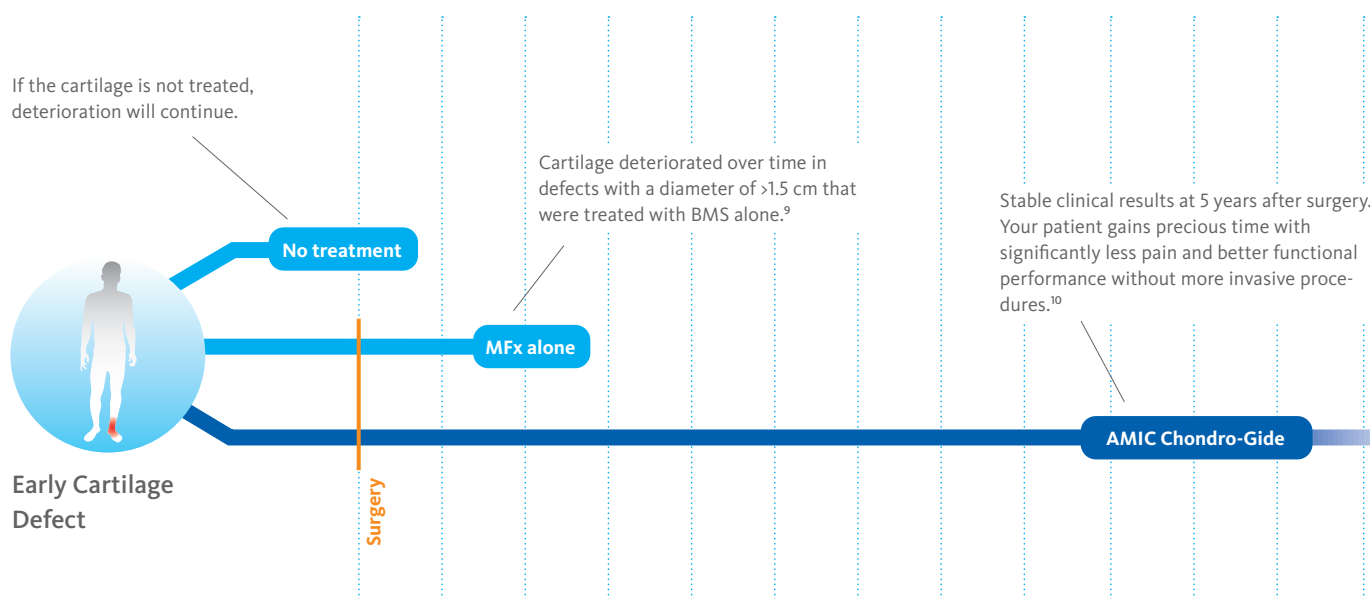
The Solution

Chondro-Gide[®], a bio-derived collagen membrane, combined with Autologous Matrix-Induced Chondrogenesis (AMIC) is a 1-step treatment for repairing cartilage lesions. Developed by Geistlich Surgery in collaboration with leading surgeons, AMIC uses bone marrow stimulation (BMS) in combination with Chondro-Gide to support the body's own healing potential.

Why Chondro-Gide

Backed by more than 10 years of clinical experience, AMIC Chondro-Gide is an effective and cost-effective technique⁸ for repairing cartilage lesions, alleviating or preventing pain, and slowing the progression of damage.

FIGURE 1: REGENERATION OF CARTILAGE BUYS PRECIOUS TIME



Developed to Support Regeneration: Chondro-Gide®

Geistlich Surgery is a leader in the field of regenerative orthopedics, which leverages the body's own ability to repair bone and cartilage.

A Better Alternative to Standard MFX

Standard MFX is commonly used in cartilage repair surgeries to recruit mesenchymal stem cells and other key bone marrow components to the site of the defect to support the regeneration of cartilage tissue. In larger lesions,¹¹ the blood clot resulting from MFX is not stable enough to withstand shear forces in the joint.

“Enhanced” MFX addresses this problem by combining standard MFX with the use of a collagen membrane, which covers and protects not only the super clot but also the repair tissue.¹⁰ Chondro-Gide is a biocompatible and fully resorbable porcine collagen membrane developed by Geistlich for use in AMIC® Chondro-Gide, a one-step enhanced MFX procedure that has been used in OCL of the talus for more than 10 years.^{12, 23}

Effective for Both Large and Small Defects^{9, 20}

AMIC Chondro-Gide was developed specifically to treat cartilage lesions in articular joint surfaces.

Chondro-Gide Features¹³

- › Bio-derived, bilayer Collagen I/III membrane¹³
- › Biocompatible and naturally resorbed¹³
- › Easy to handle: supple and tear-resistant¹³
- › Can be glued or sutured¹⁴
- › Compatible with a range of tissue regeneration techniques¹⁵
- › 1-step procedure¹³

Bioengineered to Leverage the Body's Own Healing Potential

Chondro-Gide® is a porcine bilayer Collagen I/III membrane. It has a unique structure, being compact and smooth on one side and rough and porous on the other. This provides a protective environment for the stabilization of tissue repair.^{13, 16}

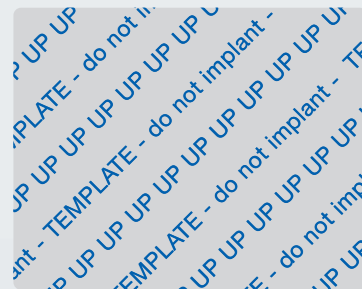CHONDRO-GIDE IS AVAILABLE IN THREE SIZES

The top layer of the membrane is marked with the word "UP" in one corner.

UP		
20 × 30 mm (30890.3)		
30 × 40 mm (30915.5)		
40 × 50 mm (30939.9)		

A STERILE ALUMINUM TEMPLATE IS INCLUDED

The size and shape of the membrane patch can be determined with the sterile aluminum template.




38 × 48 mm

A Barrier to Prevent Cell Diffusion^{10,18}

The smooth, compact top layer is also sturdy enough to protect the cells and newly forming cartilage from shear stress in the joint while the cartilage regenerates and patients undergo rehabilitation.

A Rough, Porous Bottom Layer

This layer adheres to the defect, keeping the membrane in place. Cells that are released through Mfx or other marrow stimulation techniques attach themselves to this layer, where they proliferate and produce new tissue.^{15,17}



MFx is usually the preferred treatment for OCL with a diameter of <1.5 cm. However, Choi et al.¹⁹ found that OCL with an area of >1.5 cm² treated with MFx were associated with poorer functional outcome scores.

In a systematic review based on 25 studies, with 1,868 ankles, Ramponi et al.²⁰ found a significant correlation between lesion diameter and clinical outcomes.

Bone marrow stimulation techniques should be reserved for OCL <1 cm²

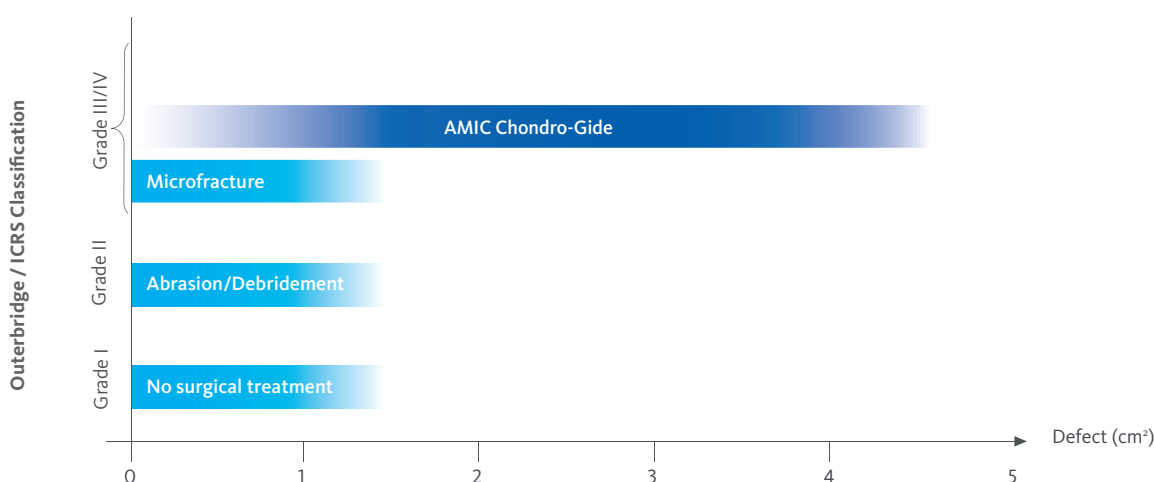
They proposed that bone marrow stimulation techniques should be reserved for OCL <1 cm², reducing the previous threshold of <1.5 cm² proposed by Chuckpaiwong et al.²¹ and Choi et al.¹⁹

The 1 cm² threshold was also supported during a 2017 consensus meeting of the International Society on Cartilage Repair of the Ankle (ISCRA). The society defined the ideal size guidelines for bone marrow stimulation (BMS) as a diameter of <10 mm, an area of <100 mm², and a depth of <5 mm.⁹ Bone grafting may already be considered for a depth of >3 mm. Based on current literature, the consensus recommendation supports the use of a scaffold to complement bone grafting.²²

AMIC Chondro-Gide is a minimally-invasive 1-step procedure that can be performed either by osteotomy²³, mini-open surgery²⁴, or in an arthroscopic²⁵ manner.

Developed by Geistlich Surgery in collaboration with leading surgeons in Europe, this technique has been effective in repairing chondral or osteochondral defects in the talus, knee, and hip.

FIGURE 2: INDICATIONS FOR AMIC CHONDRO-GIDE



The Benefits of Using AMIC® Chondro-Gide®

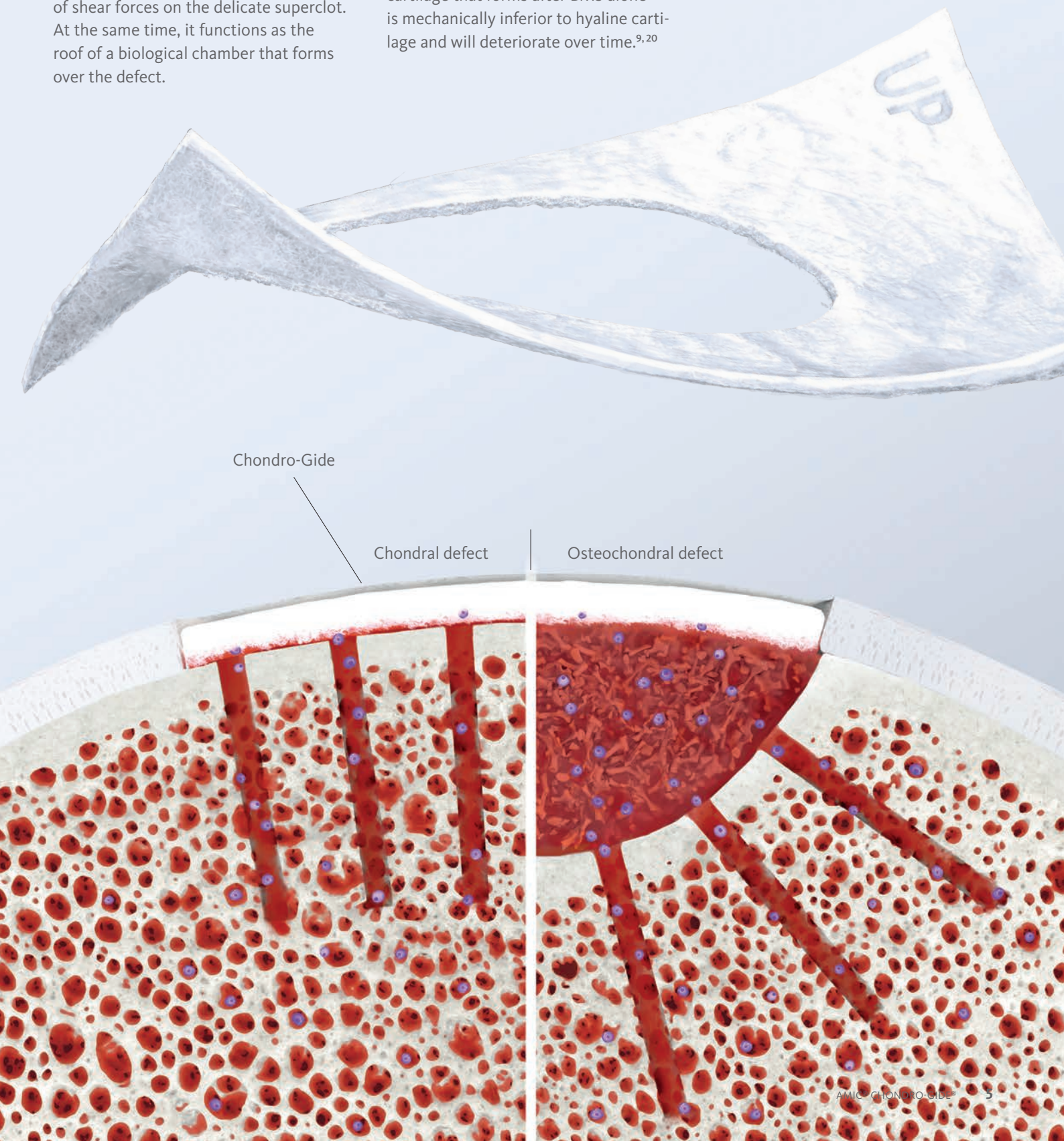
AMIC Chondro-Gide supports the body's own potential to heal itself. Damaged cartilage is removed, and then the sub-chondral bone is microfractured or drilled to release a supply of stem cells from the bone marrow.

The Chondro-Gide covers the defect and serves as a protective shield that contains the cells and minimizes the impact of shear forces on the delicate superclot. At the same time, it functions as the roof of a biological chamber that forms over the defect.

The biocompatible collagen material provides an environment for cell growth¹³ and is replaced by native tissue over time.²⁶

After MFX alone, fibrous tissue is frequently found. However, some evidence in the literature shows that after AMIC Chondro-Gide, hyaline-like tissue is formed.^{23, 27}

Studies show that the reparative fibrous cartilage that forms after BMS alone is mechanically inferior to hyaline cartilage and will deteriorate over time.^{9, 20}



INTENDED USE²⁸

Chondro-Gide® is used to cover cartilage defects treated with autologous chondrocyte implantation (ACI) or bone marrow stimulation techniques (e.g., AMIC® – Autologous Matrix Induced Chondrogenesis) and to cover meniscal or osteochondral defects. Surgical approaches include arthrotomy or arthroscopy. The defects can be acute or chronic and be caused by a fall, accident, or other traumatic events. Defects are located at articular cartilage surfaces including hyaline cartilage in the knee, hip, ankle foot, wrist, elbow, and shoulder; and fibrous cartilage including meniscus.

The defects can be acute or chronic and be caused by a fall, accident, or other traumatic events. Defects are located at articular cartilage surfaces including hyaline cartilage in the knee, hip, ankle foot, wrist, elbow, and shoulder; and fibrous cartilage including meniscus.

LIMITATIONS ON USE / PRECAUTIONS

Contraindications

Chondro-Gide should not be used in patients with:

- > a known allergy to porcine collagen
- > acute or chronic infection at surgical site
- > acute or chronic inflammatory joint disease.

Precautions

- > Chondro-Gide should only be used by surgeons, familiar with cartilage and meniscal repair techniques.
- > Chondro-Gide should be used with special caution in patients who take medications or have diseases impairing tissue regeneration.
- > Chondro-Gide should be used only under standard sterile surgical conditions.
- > Use of non-powdered gloves should be considered when preparing and handling Chondro-Gide to prevent transfer of particulate to the surgical site.
- > Insufficient fixation of the membrane can lead to its displacement.
- > Consistent with clinical practice of cartilage repair, any axial limb malalignment, joint instability or meniscal pathologies should be treated in parallel or prior to the cartilage repair procedure.
- > Abstinence from smoking during or after treatment is advised.
- > Direct mixing of Chondro-Gide with medicinal products, alcohol, disinfectants or antibiotics is not advisable and has not been studied.
- > Intraoperatively, if there is need to remove the product, complete removal can be achieved. In the postoperative phase, complete removal may not be possible since the product is intended to resorb over time
- > There is no data available on the use of Chondro-Gide during pregnancy or lactation. For safety reasons, pregnant women and breastfeeding mothers should therefore not be treated with Chondro-Gide.
- > The safety and efficacy of Chondro-Gide have not been studied in children.
- > The template must not be implanted.
- > The product is intended for single patient, single surgery use, the product must not be re-sterilized. Any unused material should be discarded.

Side Effects

As Chondro-Gide is a collagen product, allergic reactions to collagen may not be totally excluded.

Treatment Using Chondro-Gide®

Chondro-Gide is designed to provide a protective cover and keep cells released from the bone or introduced into a defect, in place. It complements regenerative treatment approaches for chondral and OCL. While enveloping the defect and the cells within it during the initial stages of the healing process, Chondro-Gide resorbs over approximately 4 months²¹ and is replaced by native tissue.

The international consensus group of experts at the ICCRA 2017²² recommended bone grafting as a suitable treatment for lesions that are > 3 mm deep. Chondro-Gide can be used in combination with bone grafting for these procedures.

Possible sources for harvesting bone grafts are the iliac crest, the distal or proximal tibia, or the calcaneus. When deciding on a point of withdrawal, consider morbidity, biology, and the amount of graft needed.

Cartilage injury can occur due to trauma or a variety of other factors, such as biomechanics and alignment or meniscus injuries. Treatment requires a holistic approach and, if necessary, concomitant interventions.

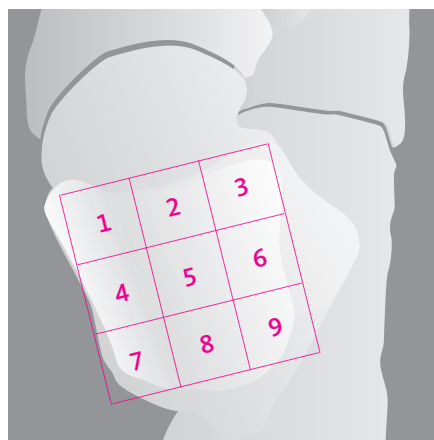
Lesion Location

The 9-zone localization system proposed by Raikin in 2007 is frequently used to document the location of lesions on the talar dome²⁹. Raikin et al. found that 63% of the lesions occurred on the medial talar zones (1,4, and 7), while 33% involved the lateral talar dome. Chew et al.¹ described two common patterns, with a focus on antero-lateral talar dome lesions and postero-medial lesions. These correspond to previous observations by Barnes et al.³⁰

Depending on the location of the lesion, an osteotomy might be necessary, especially if the reconstructive process requires the introduction of bulky material into the joint (for example, auto/allograft).

In most cases, the Chondro-Gide can be implanted without an osteotomy of the medial or lateral malleolus.^{24, 31, 32}

The approach chosen will depend on the location of the osteochondral defect.

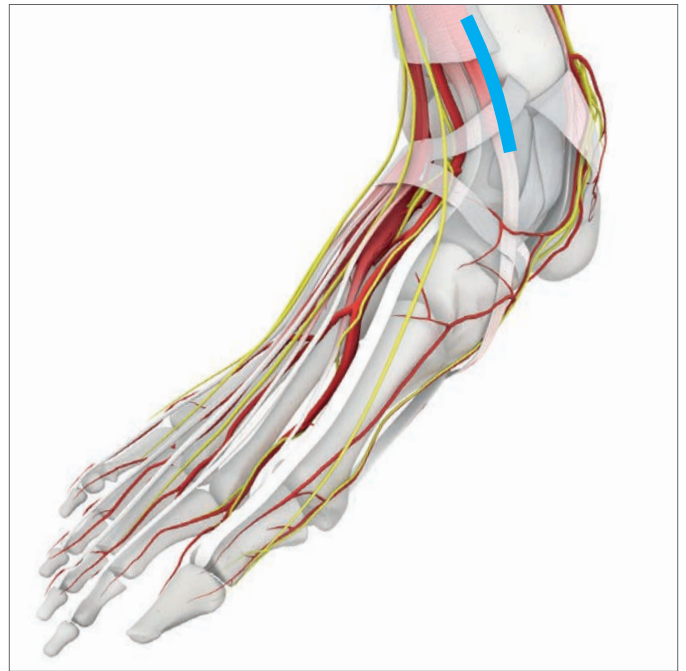

Anatomical 9-zone grid on the talar dome according to Raikin et al.²⁹



Access to the lesion with osteotomy as described by Valderrabano.²³

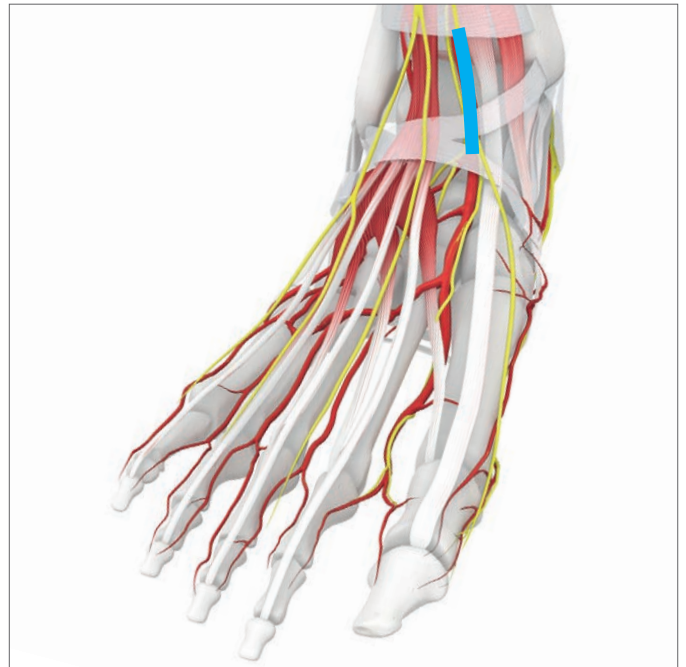
Approach to lesion as described by Walther²⁴



Medial Talar Shoulder Defects

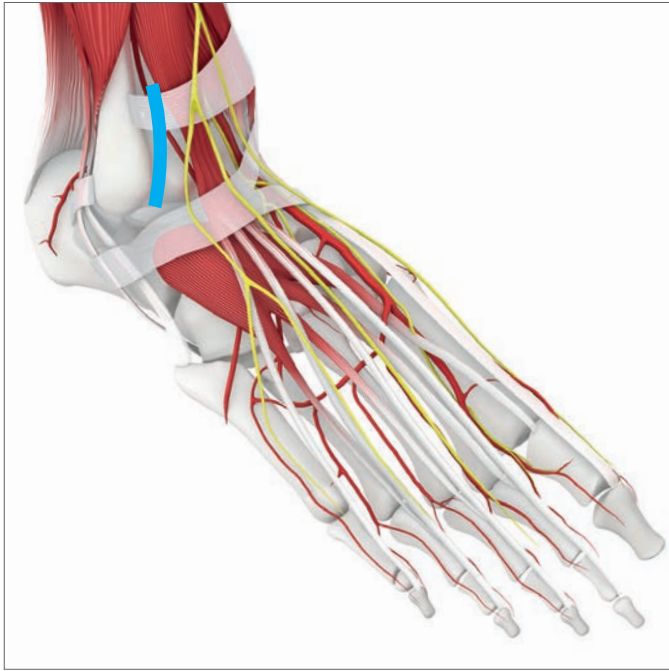
For medial talar shoulder defects, approach the lesion from the inside or outside of the extensor hallucis longus tendon.

After dissection to the level of the joint capsule, open the joint by a longitudinal incision. Distract the joint in maximum plantar flexion.



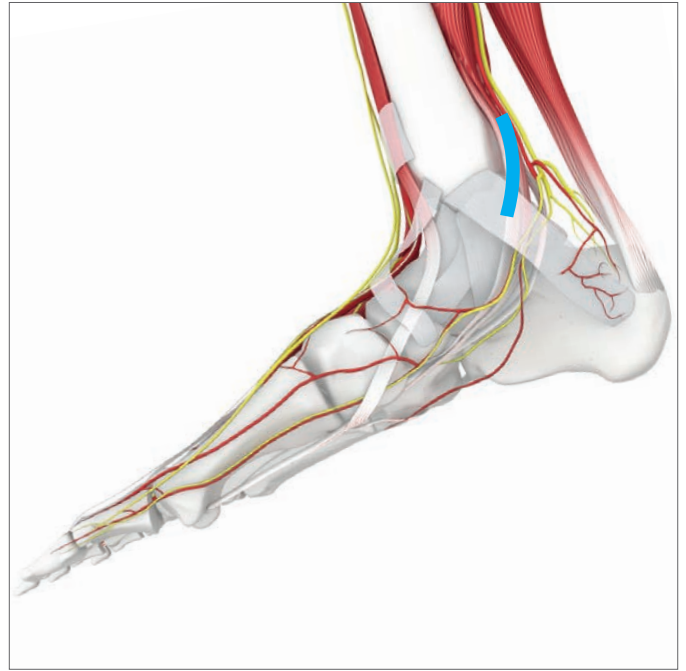Defects in the Central Area

For a defect in the central area of the talus, approach the lesion from the inside of the anterior tibial tendon.



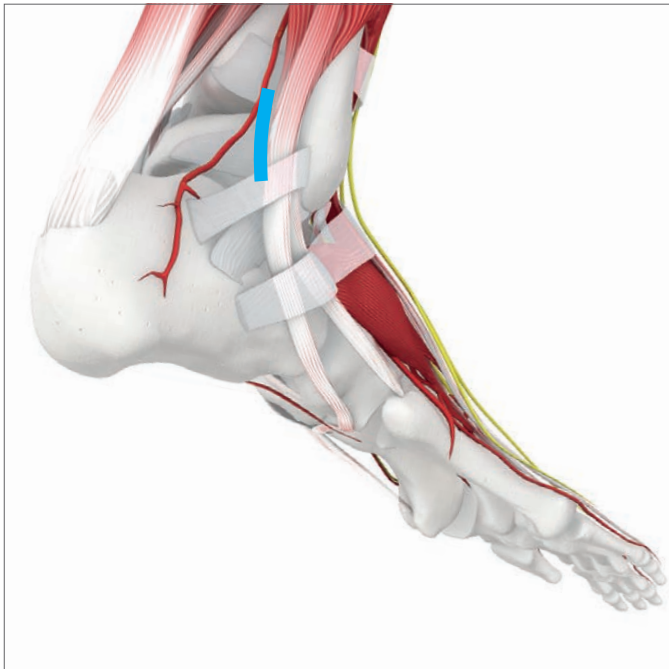Lateral Defects

For a lateral defect, use the Ollier approach.



Dorsomedial Defects

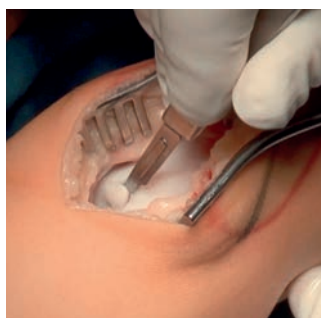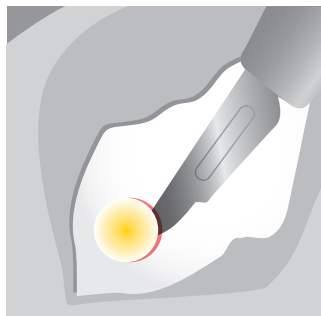
For a dorsomedial defect, approach the lesion from the back of the medial malleolus.



Dorsolateral Defects

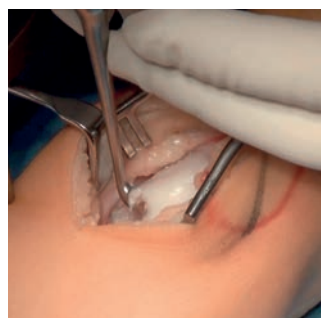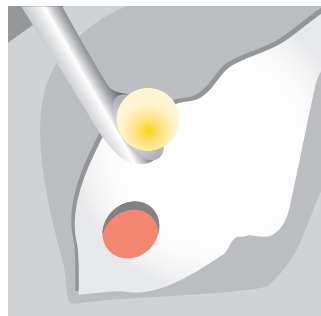For a dorsolateral defect, approach the lesion from the back of the peroneal tendons.

AMIC Technique as Described by Walther²⁴



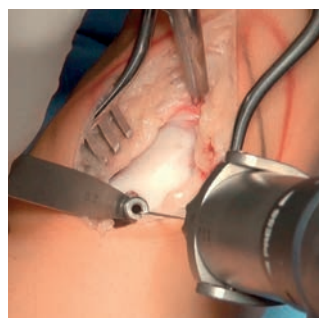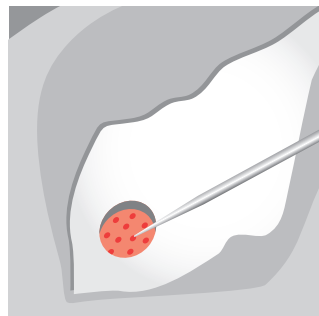
Remove Unstable Cartilage

To remove damaged, unstable cartilage, use a scalpel and curettes.



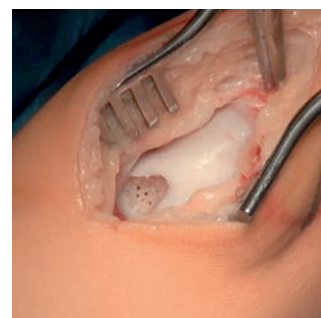
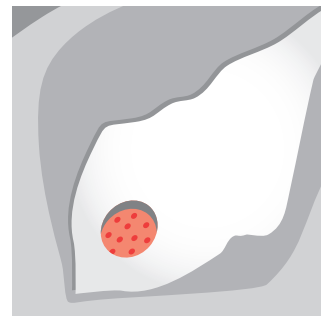
Debride Necrotic Bone and Cysts

Curette any osseous cysts and completely remove the mucoid fibrous content. Make sure the edges of the healthy cartilage are stable and perpendicular.



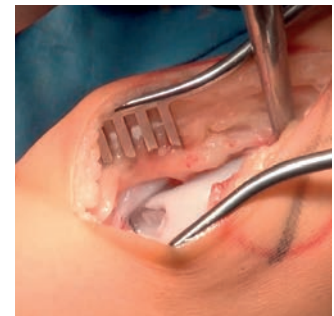
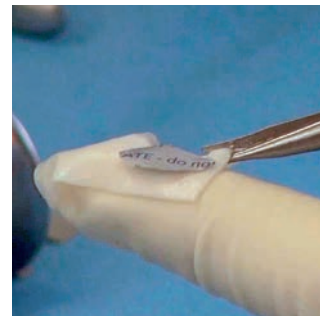
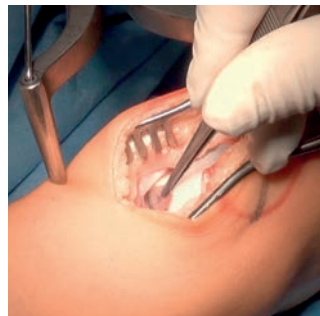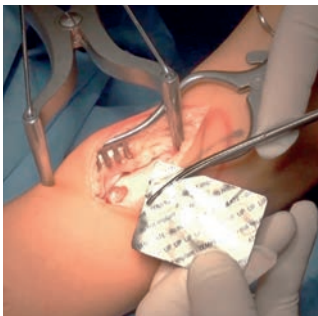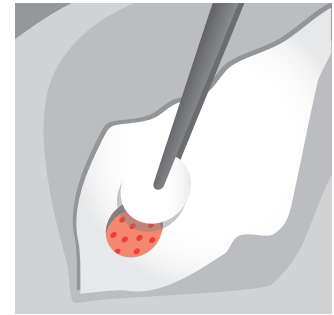
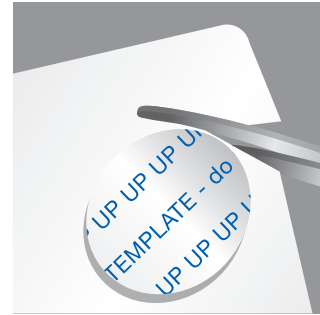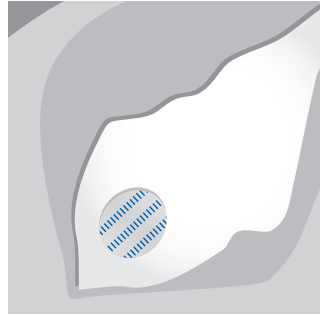
Perforate the Sclerotic Wall

Using a K-wire or microfracture awl, perforate the sclerotic wall. The image above shows perforation of the sclerotic area at the base of the lesion with multiple small drill holes (1 mm K-wire).



Place the holes from the periphery of the lesion towards the centre at intervals of 2–4 mm. In patients without cystic lesions, place the drillholes directly in the subchondral bone and preserve the smooth surface of the subchondral bone plate. Wash out the bony debris and make sure there is adequate subchondral bleeding.

Images courtesy of Prof. Dr. Markus Walther



Measure the Defect

Place the sterile aluminum template included with the Chondro-Gide® in the defect to obtain an exact impression of the defect. Cut out the imprint and transfer it onto the membrane. The side that was facing the defect must be placed on the smooth layer of the Chondro-Gide.

Trim the Chondro-Gide®

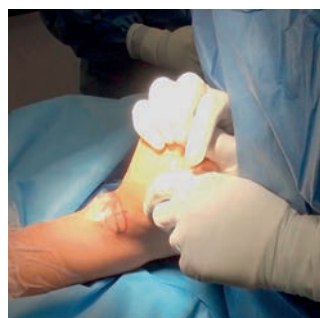
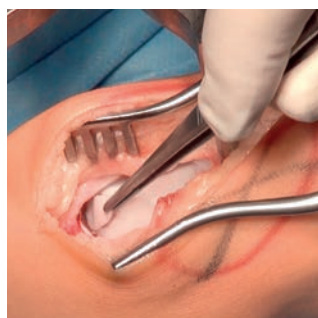
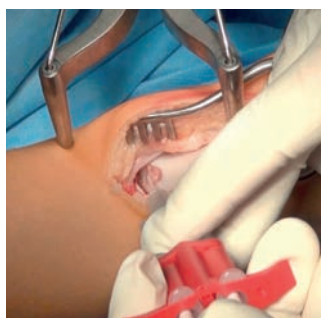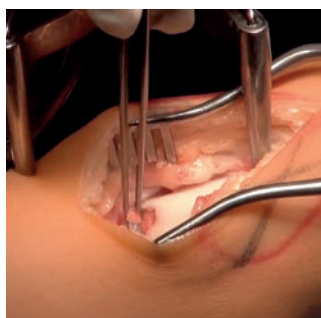
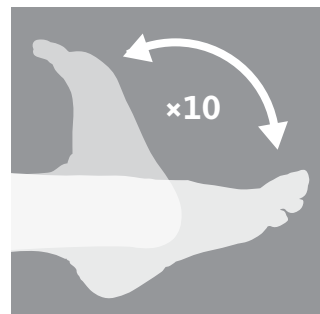
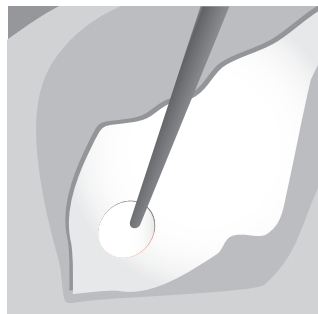
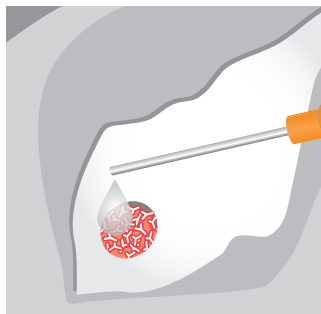
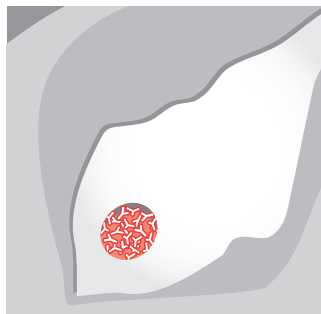
The membrane can first be hydrated in a physiological saline solution and then cut to shape. However, the dry membrane is easier to handle.

When trimming the dry Chondro-Gide, remember to cut it 10–15% smaller than the template, as the area of the Chondro-Gide will expand once moistened.

You can use a sterile pen to lightly mark the smooth (top) layer that will face the joint cavity. The “UP” sign may no longer be visible after you have cut or hydrated the membrane.

Check for precise fitting by inserting the membrane in the defect. Remove the membrane.

AMIC Technique as Described by Walther²⁴



Osseous Reconstruction in the Osteochondral Lesion

Use autologous bone to reconstruct the osseous defect up to the subchondral bone lamella. Avoid filling the defect above the level of the subchondral bone.

Note: Alternatively, you can use Orthoss® as a bone graft extender.

Secure the Chondro-Gide®

Apply fibrin glue to the bottom of the defect.

Position the Chondro-Gide

Place the Chondro-Gide in the defect with the rough (bottom) layer facing the bone surface. Gently press the membrane to affix it. Make sure the Chondro-Gide doesn't overlap with the adjacent cartilage, to avoid displacement.

Move the joint until the defect is covered by the tibia and wait for approximately 5 minutes until the fibrin glue has set.

To make sure the membrane is stable inside the defect, move the joint between plantar extension and dorsal flexion 10 times.

Clinical Summaries

Consistently Positive Results at 10 Years

Several studies have shown that Chondro-Gide® can be successfully introduced and placed without osteotomy.

Galla et al.³² conducted an analysis of patients who underwent AMIC® Chondro-Gide with autologous spongia grafting without malleolar osteotomy. Complication rates and postoperative outcomes showed improvement in relevant visual analogue scale (VAS), foot function index (FFI), and Magnetic Resonance Observation of Cartilage Repair Tissue (MOCART) scores, and no complications were noted.

The researchers concluded that AMIC Chondro-Gide can be performed through anterolateral and anteromedial arthrotomy, without malleolar osteotomy, in patients with OCL localized anterior to the midline in the sagittal plane. Successful, clinically relevant results were achieved while avoiding complications of this more complex procedure.

Walther et al.^{16,33} described the reconstruction of focal cartilage defects in the talus with mini-arthrotomy and Chondro-Gide for ICRS grade III and IV focal cartilage defects of an area of >1.5 cm².

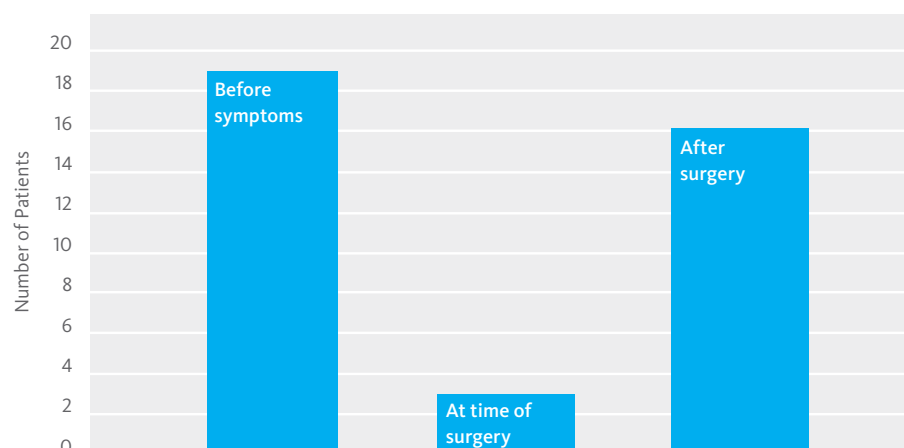
The researchers reviewed postoperative results of 14 patients for a follow-up period of >30 months. All showed improved American Orthopedic Foot and Ankle Society (AOFAS) scores, from 50 to 89 points, with equal mobility on both sides of the upper ankle joint. They observed no intraoperative complications.

They concluded that AMIC Chondro-Gide is a simple procedure. The membrane can be implanted via mini-arthrotomy alone, without osteotomy of the lateral or medial malleolus in almost all cases. They also considered AMIC Chondro-Gide to be a cost-efficient 1-step procedure compared to cartilage reconstruction with in-vitro cultured chondrocytes.

AMIC Chondro-Gide is a simple procedure that can be implanted via mini-arthrotomy alone, without osteotomy of the lateral or medial malleolus in almost all cases.

Several authors have reported the advantage of an arthroscopic procedure for the treatment of OCLs of the talus. Arthroscopic treatment can reduce sur-

FIGURE 3: NUMBER OF PATIENTS PARTICIPATING IN SPORTS (VALDERRABANO ET AL.)



gical trauma, and makes a tibial or fibular osteotomy and subsequent hardware removal unnecessary.

Valderrabano et al.²³ (Fig.3) followed 26 patients who had been treated with debridement, autologous grafting, and AMIC® Chondro-Gide® for at least 24 months. A standard anteromedial or anterolateral approach for arthrotomy was used, depending on the location of the OCL. If the OCL was inaccessible after capsular incision, a malleolar osteotomy was performed.

They also considered AMIC Chondro-Gide to be a cost-efficient 1-step procedure compared to cartilage reconstruction with in-vitro cultured chondrocytes.

The AOFAS and pain scores improved significantly. The authors also reported that patients who participated in sports before the onset of symptoms and then stopped their activities due to injury were able to resume sports activities after AMIC Chondro-Gide. In an analysis of mid-term results, Gottschalk et al.¹⁰ found that the initial

promising results from a 2-year study of the patient cohort, were seen at 5 years also. The team analyzed data for 21 patients at the mid-term, and found that the initial improvement in clinically relevant outcome measures for pain and function was sustained. Data analysis included demographics, MRI at pre-operative stage, intraoperative details, and the German version of the Foot Function Index (FFI-D) pre-operatively and at 1 and 5 years after surgery (Fig.4).

Researchers found the greatest improvement in clinical outcomes in the first year post operation. Between the 1- and 5-year follow-up further (but statistically nonsignificant) improvement could be observed. Significantly, patients returned to sports at 5 years.

Return to Sports

Wiewiorski et al.³⁴ conducted a study with a focus on sports activity following AMIC Chondro-Gide, as previous studies^{23,35} included limited information on post-operative return to low level sports activity following treatment of OCL. Treatment of the joint was corrective (alignment) and reparative (ligament repair as indicated). The osteochondral defects were treated with AMIC Chondro-Gide.

Key factors as well as overall outcome were assessed, and patients were observed to return to a similar, low level of sports activity following treatment of OCL of the talus.

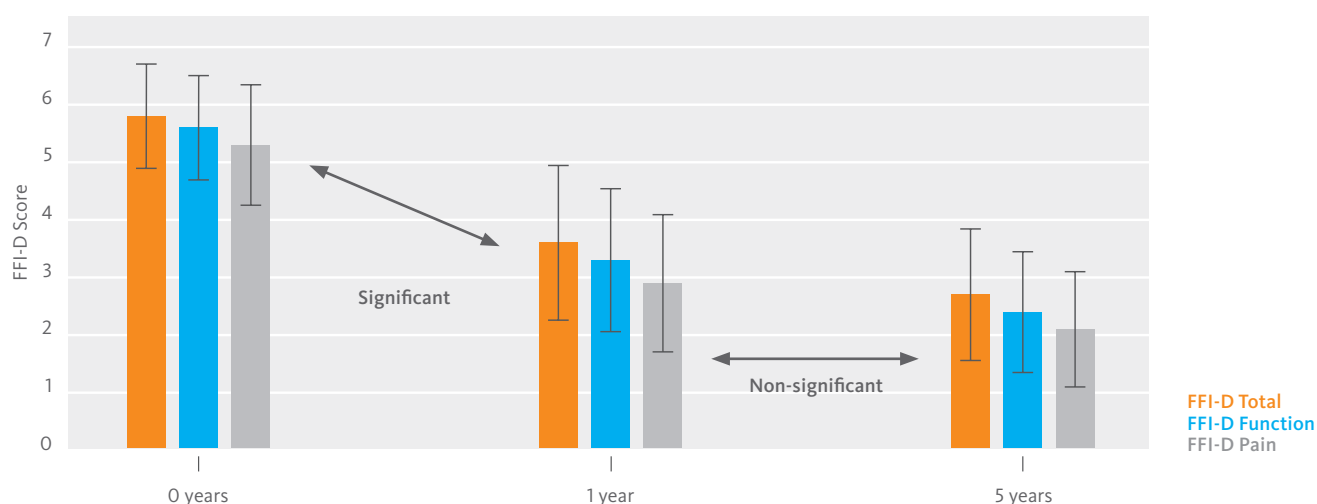
Matrix-Associated Stem Cell Transplantation (MAST)

Complex surgical procedures present additional challenges in treatment of chondral lesions. A prospective non-controlled study followed 100 patients for 5 years.³⁶

Chondral defects were treated using blood extracted from the pelvic region marrow. The lesion sites were then covered with Chondro-Gide, which was fixed with fibrin glue. It was reported that visual analogue scale foot and ankle (VAS-FA) scores improved from a pre-operative average of 42.5 to an average of 84.4 at 5 years.³⁶

MAST is a modification of AMIC Chondro-Gide, as the cells are not only harvested by MFX at the defect site. The approach to introduce autologous concentrated cells from another area of the body has been studied by other authors also.^{37,38} With MAST and other methods used to introduce cells from other areas of the body, Chondro-Gide keeps cells in place, provides a protected environment, and contributes toward regeneration of the functionality of the joint.

FIGURE 4: FFI-D SCORES OF AMIC PATIENTS AT 0, 1, AND 5 YEARS (GOTTSCHALK ET AL.)¹⁰



Rehabilitation

Immediately after Surgery

The following is a sample of what an ankle surgeon might typically recommend for rehabilitation post-surgery. As patients' needs vary, treatment should be customized to meet each person's individual needs and circumstances. Immediately after surgery, the ankle is immobilized for up to 48 hours with an orthosis or a cast to ensure wound healing. Elevating the leg and anti-inflammatory therapy is important in this early phase.

Begin lymphatic drainage and active mobilization without weight-bearing immediately after surgery. The patient should use a walker or an orthosis with partial weight-bearing (15 kg) in postoperative mobilization. Apply physical measures such as muscle stimulation or electrotherapy as needed.

Following ligament repair (reconstruction), keeping the stress on the ligaments low (max. plantar flexion 10°, free dorsal extrusion, no inversion/eversion) is very important. Apply par-

tial weight-bearing (15 kg) for 8 weeks. Thromboprophylaxis is recommended until full weight-bearing is reached.

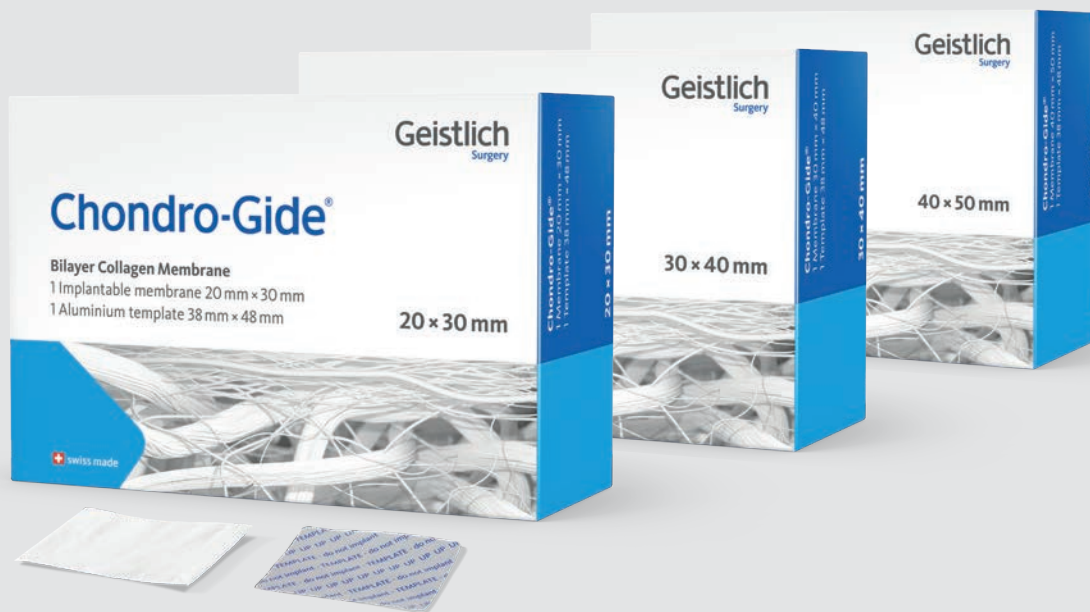3-6 Months After Surgery

Physiotherapy should accompany the healing process for 3-6 months. From month 3 onward, physiotherapy can be unconstrained. Focus on optimizing ankle flexibility and stability by building muscle (isometric muscle activation, closed kinetic chain exercises) and improving balance (proprioception). Patients can resume low-impact sports activities (e.g., hiking, swimming, and cycling) after 3 months and high-impact sports activities (e.g., jogging and ball games) after 6 months.

A balanced diet during recovery can have a positive impact on cartilage regeneration. Drinking 3 L of fluids per day, taking sufficient vitamin C, viscosupplementation with chondroitin sulfate, and avoiding alcohol and nicotine are also recommended.

	Up to W 8 post-Op	W 8 to M 3	M 3–6	M 6–12
Weight-bearing	15 kg	Increase weight-bearing, depending on symptoms	Full weight-bearing	Full weight-bearing
Mobilization	Passively and actively assisted movement	No limit	No limit	No limit
	Walker/Orthosis		Full range of movement	Full range of movement
Physiotherapy and Sports	Reduce swelling, anti-inflammatory treatment	Physiotherapy No sports	Low-impact sports (e.g., swimming, cycling)	All sports, including jogging, ball games
	No sports			

W=week, M=month
Note: This is only an example of a plan that was developed by an orthopedic surgeon (M. Walther, Schön Klinik, Munich). It must be noted that there is no agreement on one standardized algorithm in literature or among orthopedic societies.



Geistlich Chondro-Gide®

Regulatory approvals for Geistlich Chondro-Gide vary by country.

To learn more about product availability please visit www.geistlich-surgery.com or contact the Geistlich distributor in your region.



Membrane

Template (do not implant)

- 1 CHEW, KELVIN T L, 2008, Osteochondral lesions of the talus. *Annals of the Academy of Medicine*. 2008. Vol. 37, no. 1, p. 63-8 (Review).
- 2 STEELE, JOHN R., DEKKER, TRAVIS J., FEDERER, ANDREW E., LILES, JORDAN L., ADAMS, SAMUEL B., and EASLEY, MARK E., 2018, Osteochondral Lesions of the Talus. *Foot & Ankle Orthopaedics*. 2018. Vol. 3, no. 3, p. 247301141877955. DOI 10.1177/2473011418779559. SAGE Publications (Review).
- 3 BERNDT, ALBERT L. and HARTY, MICHAEL, 1959, Transchondral Fractures (Osteochondritis Dissecans) of the Talus. *The Journal of Bone & Joint Surgery*. 1959. Vol. 41, no. 7, p. 1363. DOI 10.2106/00004623-195941070-00020. Ovid Technologies (Wolters Kluwer Health) (Review).
- 4 FERKEL, 2008, Arthroscopic treatment of chronic osteochondral lesions of the talus: longterm results. *Am J Sports Med*. 2008. (Clinical Study).
- 5 HEPPEL, STEPHEN, WINSON, IAN G., and GLEW, DAVID, 1999, Osteochondral Lesions of the Talus: A Revised Classification. *Foot & Ankle International*. 1999. Vol. 20, no. 12, p. 789-793. DOI 10.1177/107110079902001206. SAGE Publications (Review).
- 6 PRADO, MARCELO PIRES, KENNEDY, JOHN G., RADUAN, FERNANDO, and NERY, CAIO, 2016, Diagnosis and treatment of osteochondral lesions of the ankle: current concepts. *Revista Brasileira de Ortopedia (English Edition)*. 2016. Vol. 51, no. 5, p. 489-500. DOI 10.1016/j.rboe.2016.08.007. Georg Thieme Verlag KG (Review).
- 7 RICHTER, MARTINUS, ZECH, STEFAN and ANDREAS MEISSNER, STEFAN, 2017, Matrix-associated stem cell transplantation (MAST) in chondral defects of the ankle is safe and effective – 2-year-follow up in 130 patients. *Foot and Ankle Surgery*. 2017. Vol. 23, no. 4, p. 236-242. DOI 10.1016/j.fas.2016.05.320. Elsevier BV (Clinical Study).
- 8 WALTHER, MARKUS, 2013, Scaffold Based Reconstruction of Focal Full Thickness Talar Cartilage Defects. *Clinical Research on Foot & Ankle*. 2013. Vol. 01, no. 02. DOI 10.4172/2329-910x.1000115. OMICS Publishing Group (Clinical Study).
- 9 HANNON et al. Debridement, Curettage, Microfracture, and Fixation Techniques for Osteochondral Lesions of the Talus, 2018. *Foot & Ankle Orthopaedics*, Vol. 3, no. 3, p. 2473011418S0006. DOI 10.1177/2473011418S00066. SAGE Publications (Consensus Meeting Report).
- 10 GOTTSCHALK, OLIVER, ALTENBERGER, SEBASTIAN, BAUMBACH, SEBASTIAN, KRIEGELSTEIN, STEFANIE, DREYER, FLORIAN, MEHLHORN, ALEXANDER, HÖRTERER, HUBERT, TÖPFER, ANDREAS, RÖSER, ANKE and WALTHER, MARKUS, 2017, Functional Medium-Term Results After Autologous Matrix-Induced Chondrogenesis for Osteochondral Lesions of the Talus: A 5-Year Prospective Cohort Study. *The Journal of Foot and Ankle Surgery*. 2017. Vol. 56, no. 5, p. 930-936. DOI 10.1053/j.jfas.2017.05.002. Elsevier BV (Clinical Study).
- 11 MITHOEFFER, K., et al. Clinical Efficacy of the Microfracture Technique for Articular Cartilage Repair in the Knee. An Evidence-Based Systematic Analysis. *AJSM*, 2009, DOI: 10.1177/0363546508328414 (Review of clinical studies).
- 12 GAO, L., et al. Early loss of subchondral bone following microfracture is counteracted by bone marrow aspirate in a translational model of osteochondral repair. *Nature Scientific Reports*, 2017, 7:45189, DOI: 10.1038/srep45189 (Pre-clinical study).
- 13 Geistlich Pharma AG data on file (Pre-clinical Study).
- 14 VOLZ, M., et al. A randomized controlled trial demonstrating sustained benefit of Autologous Matrix-Induced Chondrogenesis over microfracture at five years. *Int Orthop*, Apr 2017, 41(4), 797-804. (Clinical study).
- 15 KRAMER, J., et al. In vivo matrix-guided human mesenchymal stem cells. *Cell Mol Life Sci*, Mar 2006, 63(5), 616-626. (Clinical study).
- 16 GILLE, J., et al. Cell-Laden and Cell-Free Matrix-Induced-Chondrogenesis versus Microfracture for the Treatment of Articular Cartilage Defects: A Histological and Biomechanical Study in Sheep. *Cartilage OnlineFirst*, January 7, 2010, doi:10.1177/1947603509358721 (Pre-clinical study).
- 17 FULCO, I., et al. Engineered autologous cartilage tissue for nasal reconstruction after tumour resection: an observational first-in-human trial. *Lancet*, Jul 26 2014, 384(9940), 337-346. (Clinical study).
- 18 MUMME, M., Nasal chondrocyte-based engineered autologous cartilage tissue for repair of articular cartilage defects: an observational first-in-human trial. *Lancet*, 2016, 388 (10055) 1985-1994. (Clinical study).
- 19 CHOI, WOO JIN, PARK, KWAN KYU, KIM, BOM SOO and LEE, JIN WOO, 2009, Osteochondral Lesion of the Talus. *The American Journal of Sports Medicine*. 2009. Vol. 37, no. 10, p. 1974-1980. DOI 10.1177/0363546509335765. SAGE Publications (Clinical Study).
- 20 RAMPONI, LAURA, YASUI, YUICHI, MURAWSKI, CHRISTOPHER D., FERKEL, RICHARD D., DIGIOVANNI, CHRISTOPHER W., KERKHOFES, GINO M.M.J., CALDER, JAMES D.F., TAKAO, MASATO, VANNINI, FRANCESCA, CHOI, WOO JIN, LEE, JIN WOO, STONE, JAMES, and KENNEDY, JOHN G., 2016, Lesion Size Is a Predictor of Clinical Outcomes After Bone Marrow Stimulation for Osteochondral Lesions of the Talus: A Systematic Review. *The American Journal of Sports Medicine*. 2016. Vol. 45, no. 7, p. 1698-1705. DOI 10.1177/0363546516668292. SAGE Publications (Systematic Review).
- 21 CHUCKPAIWONG, BAVORNIT, BERKSON, ERIC M. and THEODORE, GEORGE H., 2008, Microfracture for Osteochondral Lesions of the Ankle: Outcome Analysis and Outcome Predictors of 105 Cases. *Arthroscopy: The Journal of Arthroscopic & Related Surgery*. 2008. Vol. 24, no. 1, p. 106-112. DOI 10.1016/j.arthro.2007.07.022. Elsevier BV (Clinical Study).
- 22 (Rothrauff et al.) Scaffold-Based Therapies: Proceedings of the International Consensus Meeting on Cartilage Repair of the Ankle. *Foot & Ankle International*. 2018. Vol. 39, no. 1 suppl, p. 415-475. DOI 10.1177/1071100718781864. SAGE Publications (Consensus Meeting).
- 23 VALDERRABANO, VICTOR, MISKA, MATTHIAS, LEUMANN, ANDRÉ and WIEWIORSKI, MARTIN, 2013, Reconstruction of Osteochondral Lesions of the Talus With Autologous Spongiosa Grafts and Autologous Matrix-Induced Chondrogenesis. *The American Journal of Sports Medicine*. 2013. Vol. 41, no. 3, p. 519-527. DOI 10.1177/0363546513476671. SAGE Publications (Clinical Study).
- 24 WALTHER, M., ALTENBERGER, S., KRIEGELSTEIN, S., VOLKERING, C. and RÖSER, A., 2014, Reconstruction of focal cartilage defects in the talus with miniarthrotomy and collagen matrix. *Operative Orthopädie und Traumatologie*. 2014. Vol. 26, no. 6, p. 603-610. DOI 10.1007/s00064-012-0229-9. Springer Nature (Clinical Study).
- 25 USUELLI, FEDERICO GIUSEPPE, D'AMBROSI, RICCARDO, MACCARIO, CAMILLA, BOGA, MICHELE AND DE GIROLAMO, LAURA, 2016, All-arthroscopic AMIC® (AT-AMIC®) technique with autologous bone graft for talar osteochondral defects: clinical and radiological results. *Knee Surgery, Sports Traumatology, Arthroscopy*. 2016. Vol. 26, no. 3, p. 875-881. DOI 10.1007/s00167-016-4318-4. Springer Nature (Clinical Study).
- 26 GILLE, JUSTUS, KUNOW, JULIUS, BOISCH, LUER, BEHRENS, PETER, BOS, INGEBORG, HOFFMANN, CHRISTIANE, KÖLLER, WOLFGANG, RUSSLIES, MARTIN and KURZ, BODO, 2010, Cell-Laden and Cell-Free Matrix-Induced Chondrogenesis versus Microfracture for the Treatment of Articular Cartilage Defects. *CARTILAGE*. 2010. Vol. 1, no. 1, p. 29-42. DOI 10.1177/19476035093558721. SAGE Publications (Clinical Study).
- 27 WIEWIORSKI, M., MISKA, M., KRETZSCHMAR, M., STUDLER, U., BIERI, O., and VALDERRABANO, V., 2013, delayed gadolinium-enhanced MRI of cartilage of the ankle joint: Results after autologous matrix-induced chondrogenesis (AMIC)-aided reconstruction of osteochondral lesions of the talus. *Clinical Radiology*. 2013. Vol. 68, no. 10, p. 1031-1038. DOI 10.1016/j.crad.2013.04.016. Elsevier BV (Clinical Study).
- 28 Chondro-Gide® IFU 2019, Geistlich Pharma AG.
- 29 RAIKIN, STEVEN M., ELIAS, ILAN, ZOGA, ADAM C., MORRISON, WILLIAM B., BESSER, MARCUS P. and SCHWEITZER, MARK E., 2007, Osteochondral Lesions of the Talus: Localization and Morphologic Data from 424 Patients Using a Novel Anatomical Grid Scheme. *Foot & Ankle International*. 2007. Vol. 28, no. 2, p. 154-161. DOI 10.3113/fai.2007.0154. SAGE Publications (Review).
- 30 BARNES, CHRISTOPHER J and FERKEL, RICHARD D, 2003, Arthroscopic debridement and drilling of osteochondral lesions of the talus. *Foot and Ankle Clinics*. 2003. Vol. 8, no. 2, p. 243-257. DOI 10.1016/s1083-7515(03)00016-0. Elsevier BV.
- 31 YOUNG, KI WON, DELAND, JONATHAN T., LEE, KYUNG TAI and LEE, YOUNG KOO, 2009, Medial approaches to osteochondral lesion of the talus without medial malleolar osteotomy. *Knee Surgery, Sports Traumatology, Arthroscopy*. 2009. Vol. 18, no. 5, p. 634-637. DOI 10.1007/s00167-009-1019-2. Springer Nature.
- 32 GALLA, MELLANY, DUENSING, IAN, KAHN, TIMOTHY L. and BARG, ALEXEJ, 2018, Open reconstruction with autologous spongiosa grafts and matrix-induced chondrogenesis for osteochondral lesions of the talus can be performed without medial malleolar osteotomy. *Knee Surgery, Sports Traumatology, Arthroscopy*. 2018. DOI 10.1007/s00167-018-5063-7. Springer Nature (Clinical Study).
- 33 VALDERRABANO, VICTOR, BARG, ALEXEJ, ALATTAR, ABDULHAMEED and WIEWIORSKI, MARTIN, 2014, Osteochondral Lesions of the Ankle Joint in Professional Soccer Players. *Foot & Ankle Specialist*. 2014. Vol. 7, no. 6, p. 522-528. DOI 10.1177/1938640014539811. SAGE Publications (Case Studies).
- 34 WIEWIORSKI, MARTIN, WERNER, LORENZO, PAUL, JOCHEN, ANDERSON, ANDREW E., BARG, ALEXEJ and VALDERRABANO, VICTOR, 2016, Sports Activity After Reconstruction of Osteochondral Lesions of the Talus With Autologous Spongiosa Grafts and Autologous Matrix-Induced Chondrogenesis. *The American Journal of Sports Medicine*. 2016. Vol. 44, no. 10, p. 2651-2658. DOI 10.1177/0363546516659643. SAGE Publications (Clinical Study).
- 35 PAUL, JOCHEN, SAGSTETTER, MICHAEL, LÄMMLE, LENA, SPANG, JEFFREY, EL-AZAB, HOSAM, IMHOFF, ANDREAS B. and HINTERWIMMER, STEFAN, 2012, Sports Activity After Osteochondral Transplantation of the Talus. *The American Journal of Sports Medicine*. 2012. Vol. 40, no. 4, p. 870-874. DOI 10.1177/0363546511435084. SAGE Publications (Clinical Study).
- 36 RICHTER, MARTINUS and ZECH, STEFAN, 2018, Matrix-associated Stem Cell Transplantation (MAST) in Chondral Lesions at the Ankle as Part of a Complex Surgical Approach. *Foot & Ankle Orthopaedics*. 2018. Vol. 3, no. 3, p. 2473011418S0040. DOI 10.1177/2473011418S00404. SAGE Publications (Clinical Study).
- 37 DE GIROLAMO, LAURA, SCHÖNHUBER, HERBERT, VI-GANÒ, MARCO, BAIT, CORRADO, QUAGLIA, ALESSANDRO, THIEBAT, GABRIELE and VOLPI, PIERO, 2019, Autologous Matrix-Induced Chondrogenesis (AMIC) and AMIC Enhanced by Autologous Concentrated Bone Marrow Aspirate (BMAC) Allow for Stable Clinical and Functional Improvements at up to 9 Years Follow-Up: Results from a Randomized Controlled Study. *Journal of Clinical Medicine*. 2019. Vol. 8, no. 3, p. 392. DOI 10.3390/jcm8030392. MDPI AG (Clinical Study).
- 38 STEINWACHS, MATTHIAS R., WAIBL, BERNHARD, WOPPERER, STEPHANIE and MUMME, MARCUS, 2014, Matrix-Associated Chondroplasty: A Novel Platelet-Rich Plasma and Concentrated Nucleated Bone Marrow Cell-Enhanced Cartilage Restoration Technique. *Arthroscopy Techniques*. 2014. Vol. 3, no. 2, p. e279-e282. DOI 10.1016/j.eats.2014.01.002. Elsevier BV (Clinical Study).



www.geistlich-surgery.com

Headquarters Switzerland

Geistlich Pharma AG
Business Unit Surgery
Bahnhofstrasse 40
CH-6110 Wolhusen
Phone +41 41 492 55 55
Fax +41 41 492 56 39
surgery@geistlich.com
www.geistlich-surgery.com

France

Geistlich Pharma France SA
Parc des Reflets
165 avenue du Bois de la Pie - BP 43073
FR-95913 Roissy CDG Cedex
Phone +33 1 48 63 90 26
Fax +33 1 48 63 90 27
surgery@geistlich.com
www.geistlich.fr

Germany

Geistlich Biomaterials
Vertriebsgesellschaft mbH
Schneidweg 5
D-76534 Baden-Baden
Phone +49 7223 96 24 0
Fax +49 7223 96 24 10
surgery@geistlich.de
www.geistlich.de

Italy

Geistlich Biomaterials Italia S.r.l.
Via Castelletto, 28
I-36016 Thiene VI
Phone +39 0445 370 890
Fax +39 0445 370 433
surgery@geistlich.com
www.geistlich.it

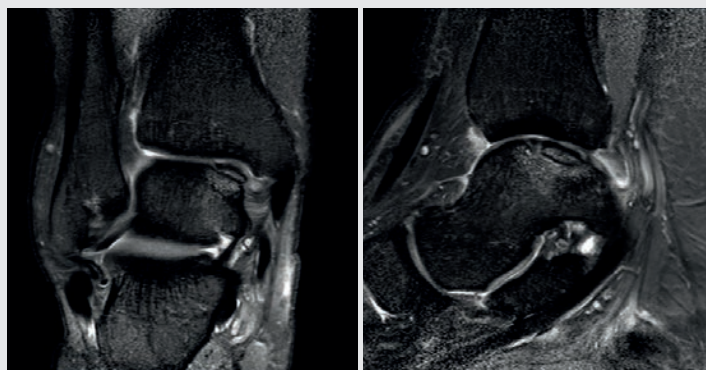
Brazil

Geistlich Pharma do Brasil
Av. Brig. Faria Lima
1461 - 13 andar - cj. 131/134
01452-002 São Paulo - Brazil
Phone (11) 3097-2555
Fax (11) 3097-2550
info@geistlich.com.br
www.geistlich.com.br

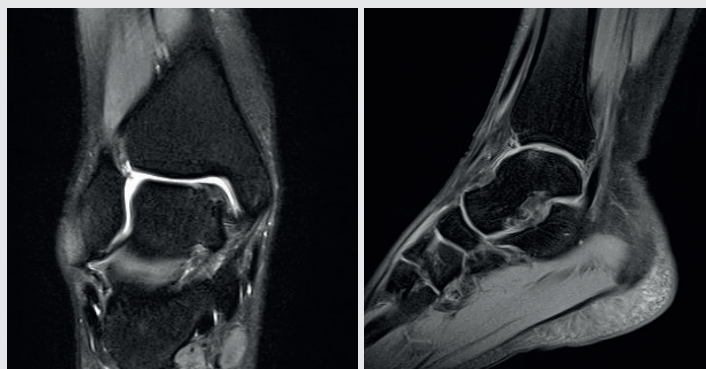
South Korea

Geistlich Pharma Korea Co Ltd.
5F, Daehyun Blue Tower
51-1 Gangnam-daero, Seocho-gu
KR-06628 Seoul
South-Korea
Tel.: + 82 2 553 7632
Fax: + 82 2 553 7634
info@geistlich.co.kr
<https://www.geistlich.co.kr>

More than 10 Years Clinical Experience in the Ankle Joint



The preoperative MRT-diagnostic image shows an osteochondral lesion $>1.5 \text{ cm}^2$ on the medial edge of the talus. Images courtesy of Prof. Dr. Markus Walther



After 3 years, the cancellous bone graft has been partially resorbed and the defect area is filled completely with regenerated cartilage. In comparison to the lateral talus, the edge on the radial side is slightly rounded. Images courtesy of Prof. Dr. Markus Walther

To start using AMIC® Chondro-Gide® to alleviate or prevent patient pain and slow the progression of cartilage damage, contact your local Geistlich representative.